

Definite diagnosis of viral haemorrhagic septicaemia infected farmed rainbow trout and histopathologic study of acutely diseased fish in Iran

Rahnama R.^{1*}; Peyghan R.¹; Seyfi Abad Shapouri M.R.²; Rezaie A.²; Shahbazian N.³

Received: August 2017

Accepted: November 2018

Abstract

Viral haemorrhagic septicaemia (VHS) is one of the most important viral diseases in rainbow trout that has caused great losses to the Iranian rainbow trout aquaculture industry in few recent years. In the early autumn of 2015, in order to identify the possible causes of loss, farmed fish were sampled from the epicenter where massive mortalities and economic losses had occurred. Three samples were collected from relevant tissues (i.e. liver, kidney, spleen, heart, and brain) of the rainbow trout with clinical signs of VHS disease. The samples were stored in 70% ethanol, Eagle's minimum essential medium (EMEM) and 10% formalin to perform RT-PCR, cell-culture and histopathology examinations, respectively. A virus was isolated using fish cell lines inoculated with a homogenate of the internal organs. Sequencing analysis of truncated N gene confirmed the existence of VHS virus. RT-PCR and histopathology tests indicated the suitability and simplicity of the test as a paraclinical diagnostic method for VHS virus in the region. Haemorrhage, necrosis and other changes in histological sections of the diseased fish demonstrated pathological changes identical with the typical VHS pathology in target organ of the virus (i.e. heart, spleen, liver and kidney). To our knowledge, this is one the first studies that fully focused on the identification of VHSV from farmed trout in Iran by using histopathology examinations.

Keywords: Histopathology, Rainbow trout, RT-PCR, Viral haemorrhagic septicaemia

1-Department of Aquatic Health, Faculty of Veterinary, Shahid Chamran University of Ahvaz, Ahvaz, Iran.

2-Department of Pathobiology, Faculty of Veterinary, Shahid Chamran University of Ahvaz, Ahvaz, Iran.

3-Aquatic Animal Health and Diseases Management Department, Iranian Veterinary Organization, Tehran, Iran

*Corresponding author's Email: royarahnama60@yahoo.com

Introduction

Viral haemorrhagic septicaemia (VHS) is a severe disease with a wide distribution in marine and fresh water fish species (Einer-Jensen *et al.*, 2004; Dale *et al.*, 2009) that causes high mortality in farmed rainbow trout (*Onchorhynchus mykiss*) (Lorenzen *et al.*, 1999; Thiery *et al.*, 2002; Skall *et al.*, 2005). Viral haemorrhagic septicaemia virus (VHSV) belongs to the Rhabdoviridae family and *Novirhabdovirus* genus with a negative-stranded RNA (Nishizawa *et al.*, 2002). The VHS virus genome consists of approximately 12000 nucleotides (nt) and six genes encoding five structural proteins: the nucleocapsid protein (N), the polymerase-associated protein (P), matrix (M), the glycoprotein (G), RNA polymerase (L) and non-structural protein (NV) (Benmansour *et al.*, 1997; Einer-Jensen *et al.*, 2004; Duesund *et al.*, 2010).

VHSV was first isolated from rainbow trout in Denmark in 1962 (Lorenzen *et al.*, 1999; Einer-Jensen *et al.*, 2004). During the last decade, VHS viruses have been reported in different parts in the Northern hemisphere, ranging from the West and East Europe to the Gulf of Alaska and Japan (Snow *et al.*, 2005; Garver *et al.*, 2013). VHS mainly impacts the rainbow trout farming industry and it can cause up to 90% mortality in affected

farms (Benmansour *et al.*, 1997; Moran and Fofana, 2007).

The cause of death is considered to be impairment of osmotic balance. Clinical signs include: edema and red hemorrhagic spots around the eyes and on the gills, and hemorrhages in the viscera and muscles. Based on the clinical and pathological signs VHS infections are classified into three phases: acute, chronic and nervous. The acute phase of the disease is usually accompanied by high losses. Notable mortality occurs in chronically infected fish also, but the process is prolonged. Fish display symptoms such as lethargy, dark color, exophthalmia, and severe anemia, but no gross hemorrhage. At late stages of the epidemic, mortality eventually ceases and survivors may become carriers of the disease and shed the virus with urine and sexual fluids (Wolf, 1988; Soliman and El-Matbouli, 2006).

In the diseased fish, degenerative changes and necrosis are found in most parts of the internal organs of the fish. However the microscopic changes are generally confined to the liver, kidneys, spleen, and heart (i.e. focal hepatic necrosis, necrosis and hemorrhage in hematopoietic tissue and necrosis of the intestinal submucosa (Yasutake and Snieszko, 1970; Amlacher *et al.*, 1980; Wolf, 1988). Despite the intensive research on development of a vaccine or therapeutic methods against VHS for three decades, there are no commercial vaccines and no effective therapies available

for this disease (Byon *et al.*, 2005; Vinay *et al.*, 2013).

Molecular techniques are potentially fast and sensitive tools to diagnose fish viral diseases (Altinok and Kurt, 2003; Pierce *et al.*, 2013). In the diagnosis of VHS, according to the full or partial sequencing of the gene N or NV and G, four genotypes have been identified for VHSV. These genotypes show some degree of host and geographic specificity (Nishizawa *et al.*, 2002; Duesund *et al.*, 2010; Pierce *et al.*, 2013).

According to report from FAO (Fisheries FA, 2010), rainbow trout production predominantly occurs in Chile, Iran, Turkey, Norway, US, Denmark and France. The increasing development of trout production has been accompanied by an increase in disease problems (Collet, 2014). Such problems were reported in Iranian rainbow trout farms since early autumn of 2015, which caused significant economic losses to the farmers (Rahnama *et al.*, 2018). Therefore, rapid detection and identification of specific pathogens can assist in successful implementation of programs to prevent the spread of disease and minimize economic losses due to viral diseases such as VHS.

One of provinces that has in the recent years frequently suffered from VHS mortalities in rainbow trout farms is Chaharmahal-Bakhtiari Province (located in the west of Iran). According to the

regional authorities in some farms mortality resulted in more than 80% stock loss. Moribund fish usually showed typical clinical signs of VHS, such as uncoordinated swimming behavior, loss of appetite, darkening of skin, exophthalmia, and hemorrhage.

The disease has been identified as VHS by the Iranian Veterinary Organization; however, so far histopathological and molecular identification of the disease has not been reported in this province. The major objectives of the present study were detection of causative agents of the outbreaks in recent years in local rainbow trout farms and investigation of histopathological protocols for identification and study of the diseased fish. As amplification of a 1-505 bp region of VHSV N gene detected all genotypes of VHSV (OIE, 2009), we used similar primers for detection of the virus in the present study. Histological techniques enable description of tissue pathology and highlight the temporal cascade of cellular changes, hence, in this study we focused on the histological changes of the VHS.

Materials and methods

Sampling

In the early autumn of 2014, diseased or moribund fish (150 ± 30) with VHS behavioral and gross pathological symptoms were collected from the farms which were suspected to have contracted VHS by the Aquatic

Research Section of Chaharmahal-
Bakhtiari Provincial Veterinary

Organization (Fig. 1).

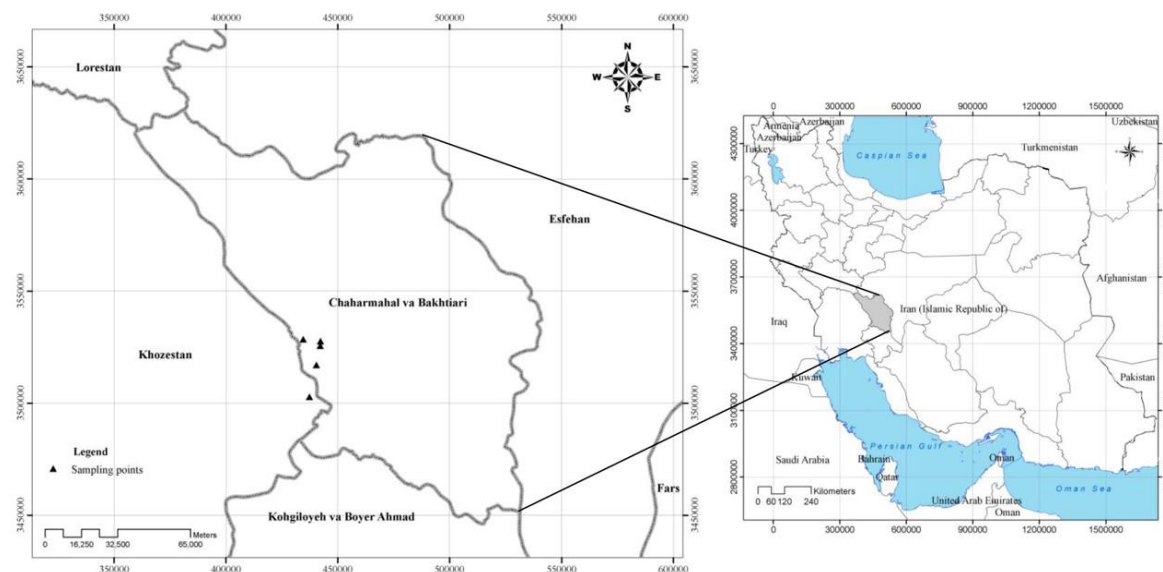


Figure 1: Sampling localities in Chaharmahal-Bakhtiari Province, Iran.

Fish were delivered to the laboratory on ice or frozen, depending on the delivery time. For viral RNA extraction samples were kept on ice during delivery if it took less than 72 h; otherwise, they were frozen quickly and dispatched (Garver *et al.*, 2013).

For histopathologic studies 1 cm³ samples of heart, kidney, spleen and liver were fixed in formalin (10% phosphate-buffered formalin). For cell culture, pooled tissue samples, as named above, were transferred to 9 volumes of minimum essential ingredients EMEM, pH: 7.6, containing 12.5% Tris-Hcl 1%, 10% bovine serum and 100 µg ml⁻¹ gentamicin. All examinations were done on the samples according to Dale *et al.* (2009).

RNA extraction

In order to extract viral RNA, kidney, heart, brain and spleen tissues were taken and frozen in liquid nitrogen.

After homogenization, 20-25 mg of the tissue homogenate was collected and stored in RNA later solution (Qiagen®, Germany) until RNA extraction. RNA was extracted using a commercial kit (RNax; Qiagen®, Germany) according to the manufacturer's instructions. RNA was eluted in 30 µl diethylpyrocarbonate (DEPC)-treated water and stored at -70 °C until required (Soliman and El-Matbouli, 2006).

Reverse transcription and polymerase chain reaction (RT-PCR)

The primary diagnostic RT-PCR was performed using QIAGEN One-step RT-PCR kit (Qiagen, Germany). The reverse (5'-GCGGTGAAGTGCTGCAGTTCCC-3') and forward (5'-ATGGAAGAAGAAATTCGTGAAGCG-3') primers from

were used for RT-PCR (OIE, 2009). The reaction mixture included 5 µl of extracted RNA, 2 µl 10 mM dNTP, 10 µl 5 x RT-PCR reaction buffer and 2 µl enzyme mix. PCR cycles were started with one step of initial denaturation at 94°C for 3 min and amplification was continued with 30 cycles of 94 °C for 30 sec, 55 °C for 30 sec, and 72 °C for 90 sec, and a final extension of 7 min at 72°C. Quality and quantity of the PCR products were analyzed via electrophoresis on 1% agarose gel in TAE buffer (Einer-Jensen *et al.*, 2004; OIE, 2009).

Amplified 505-bp fragment PCR product was extracted using GF1 Ambiclean (Gel & PCR) according to manufacturer's instruction (Vivantis®, Malaysia) and was stored at -20 °C.

Cloning and sequencing

Directional cloning of PCR product was performed according to the method described in Benmansour *et al.* (1997). PCR product and PTZ vector ligated to DH5α lineage of *Escherichia coli*. This bacterium (*E. coli*) was cultured on agar LB medium containing ampicillin and the cultured colonies were selected as clones possessing vector and possibly N-VHS gene selection. Some of the cultured colonies were randomly selected and screened by colony PCR examination. The recombinant plasmids were extracted using plasmid extraction kit (Vivantis®, Malaysia) and were sequenced (Bioniz®, Korea).

Cell culture

Virus isolation was performed in the epithelial cell line from *Epithelioma papulosum cyprini* (EPC) cells (Lorenzen *et al.*, 1999). Tissue samples from kidney, heart, spleen, and brain were diluted with nine volumes of minimum essential medium (MEM, Sigma, St. Louis, Missouri, USA) containing Earle's salt, L-glutamine, 25 mM Heps, 10% fetal bovine serum (FBS), 100 ng ml⁻¹ of streptomycin sulfate, 100 IU penicillin G, and homogenized using a Biomaster stomacher at 4°C at a speed of 3000 for 15 min (Elsayed *et al.*, 2006; Rahnama *et al.*, 2018). Homogenates were left to settle at 4 °C for 4h.

A part of the supernatant was filtered using 0.45 µm filters and 150 µl sterile filtered fluid was added to monolayer culture. Flasks were kept at 15 °C and examined for Cytopathic effect (CPE) for 21-28 days (Estepa *et al.*, 1993; Skall *et al.*, 2004; Dadar *et al.*, 2015).

Histological examination

Fixed tissue samples of liver, kidney, spleen, heart, and brain were dehydrated, cleared, embedded in paraffin wax and sectioned according to routine procedures of the pathology lab and stained with haematoxylin and eosin (H&E). Then the slides were analyzed by light microscopy (Raja-Halli *et al.*, 2006; Dale *et al.*, 2009; Ahmadi *et al.*, 2011).

Results

Amplification, sequence determination and cloning of the N-VHS gene

Electrophoresis of RT-PCR product in 1% agarose gel compared to a 1 kb size marker (Fermentas[®], Lithuania) showed DNA fragments of about 505 bp (Fig. 2). Following amplification of this segment and cloning, the appearance of colonies on LB agar medium containing ampicillin indicated the success of bacterial transformation by the plasmid.

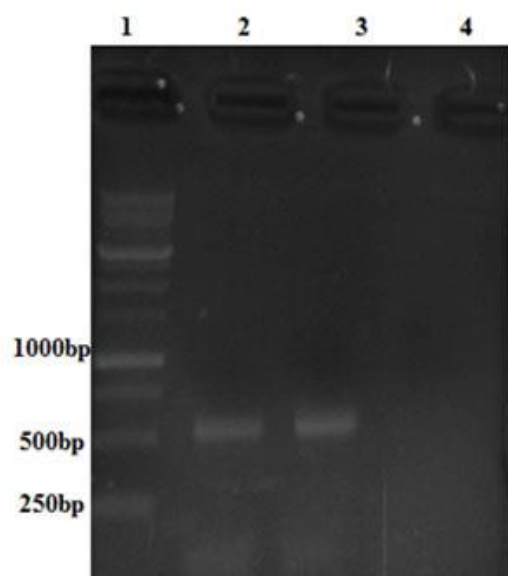


Figure 2: Electrophoresis of PCR product, 1kb DNA (lane 1) RT-PCR product replicates, 505 bp (lanes 2 and 3) and negative control (lane 4).

Virus isolation

The VHSV isolates were separated from homogenized pooled sample of moribund rainbow trout in the first passage on EPC cells. Cytopathic effects appeared in 5-7 days post

To ensure that the transformed bacteria contain a recombinant plasmid, bacterial colonies were screened by PCR. The results of screening for some colonies are illustrated in Fig. 3.

Sequencing of the insert in three recombinant plasmids followed by evaluation of sequences by BLAST search in NCBI, revealed that the cloned DNA segment was 100% similar to the sequence of VHS N-gene. Sequencing also indicated that the insert was successfully cloned in PTZ.

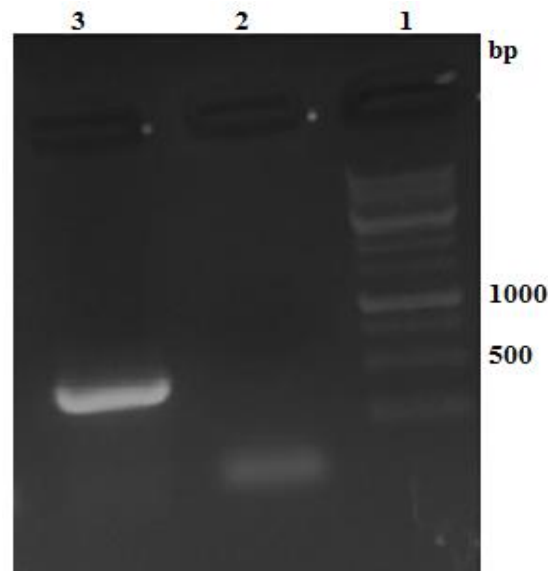


Figure 3: Colony PCR of randomly selected colonies. Lane 1, 1kb DNA ladder, lanes 2: negative colonies, lanes 3: colonies possessing recombinant plasmid (505bp).

inoculation. These effects consist of rounding of cells, fusion with adjacent cells to form syncytia, and the appearance of nuclear or cytoplasmic inclusion bodies, resulting in total destruction of monolayer (Fig. 4).

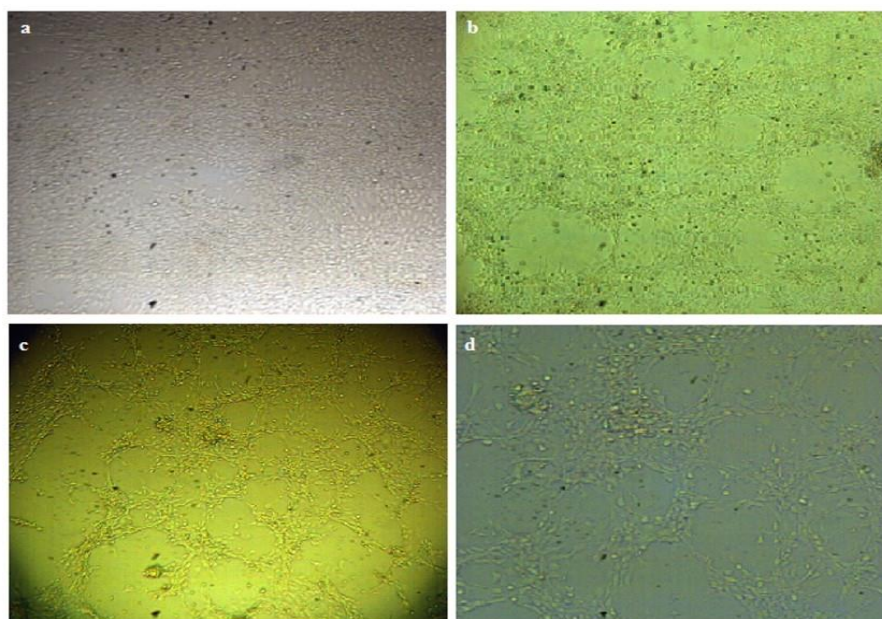


Figure 4: Control cell culture (a) and cytopathic effect caused by VHSV in EPC cell line at day 3 (b), 5 (c) and 7 (d) post-inoculation.

Histopathological examination

Microscopic examination revealed widespread necrotic foci of varying sizes in the liver. Remnants of the dead cells were seen in these areas. Hepatocyte apoptotic bodies were common throughout the liver tissue (Fig. 5a and 5b). Also nuclear alteration and chromatin margination were detected (Fig. 5b). Engorgements of sinusoids with erythrocytes were detected in some livers (Fig. 5c).

Microscopic examination of kidney revealed severe necrosis of hematopoietic tissue and substituted by erythrocytes, increasing of melanomacrophage centers and scattered black pigments (Fig. 6a, 6b and 6e). There was diffuse tubular degeneration, characterized by tubular cell vacuolation (Fig. 6d). Membranous glomerulonephritis with the accumulation of eosinophilic materials

in the urinary spaces (proteinuria) and extending of the mentioned space were seen (Fig. 6b). Also eosinophilic intracytoplasmic inclusion bodies were detected in tubular cells (Fig. 6c).

Histopathological study of spleen showed diffuse necrosis of hematopoietic tissue and accumulation of erythrocytes (Fig. 7). Heart microscopic examination revealed necrosis of cardiac muscle cells and accumulation of erythrocytes beneath the epicardium (Fig. 8a and 8b).

Histopathological examination of brain revealed meningoencephalitis in the optic lobe and cerebellum. There were prominent thickenings of the pia matter due to infiltration of mononuclear cells (Figs. 9a, 9b and 10). Also ischemic cell changes were observed in the perikaryon of neurons which are characterized by shrinkage and dark blue cell bodies. Gliosis and

increasing of Virchow robin spaces were seen (Fig. 11a and 11b).

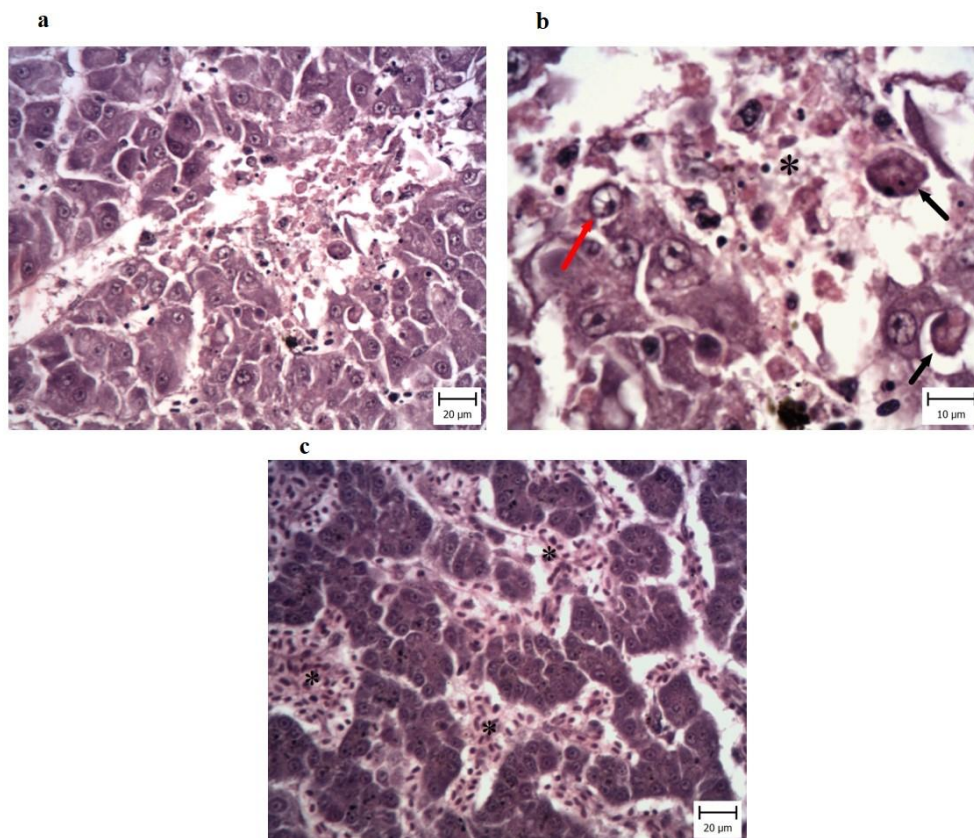


Figure 5: Liver of Rainbow trout (*Onchorhynchus mykiss*). a: One area of hepatocytes necrosis (H&E, Bar: 20µm). b: A part of Figure 4a with higher magnification. In this area remnant of dead hepatocytes (asterisk) and apoptosis of hepatocytes (black arrows) are obvious. Also nuclei of adjacent normal hepatocytes show changes include margination of chromatin (red arrow) (H&E, Bar: 10µm). c: Congestion of sinusoids (asterisk) which is characterized with accumulation of erythrocytes and sinusoids are distended. (H&E, Bar: 20µm).

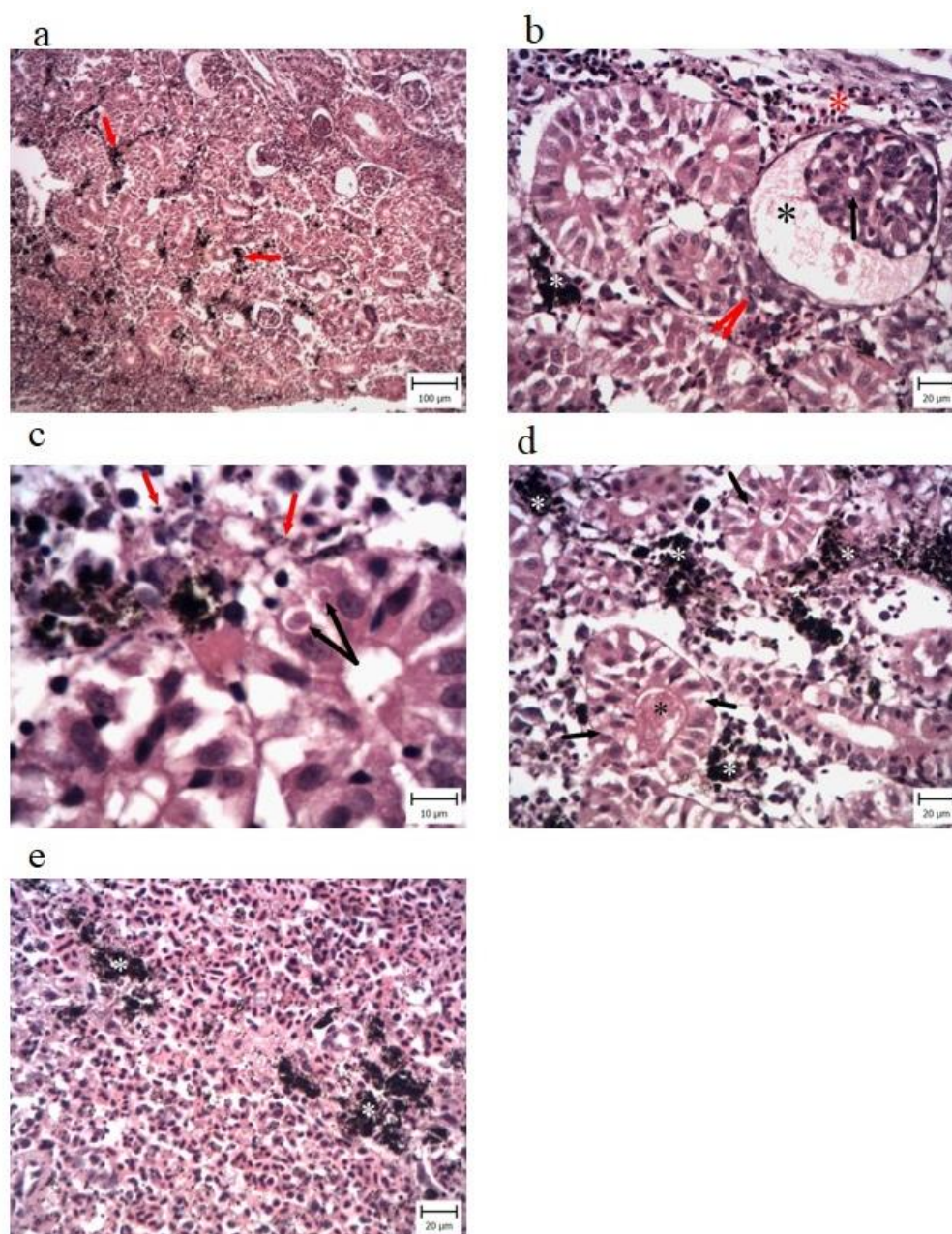


Figure 6: a: Kidney of Rainbow trout (*Onchorhynchus mykiss*). a: Increase of melanomacrophage aggregates (red arrows) (H&E, Bar: 100µm). b: A part of Figure 6a with higher magnification. The membranous glomerulonephritis (black arrow) and increase of urinary space (black asterisk) which is filled with eosinophilic materials are seen. Aggregation of melanomacrophages between tubules (white asterisk) and vacuolation of tubular cells are obvious (red arrows). Substitution of haematopoietic tissue with erythrocytes is seen (red asterisk) (H&E, Bar: 20µm). c: Black pigments (red arrows) which are scattered in the tissue. Also intracytoplasmic inclusion bodies are indicated (black arrows) (H&E, Bar: 10µm). d: The tubular degeneration (arrows) and existence of eosinophilic materials in the lumen of tubules (black asterisk) are obvious. Aggregation of melanomacrophages between tubules (white asterisk) is also seen (H&E, Bar: 20µm). e: Increased number of erythrocytes which are diffusely seen, and aggregation of melanomacrophages (white asterisk) are observed (H&E, Bar: 20µm).

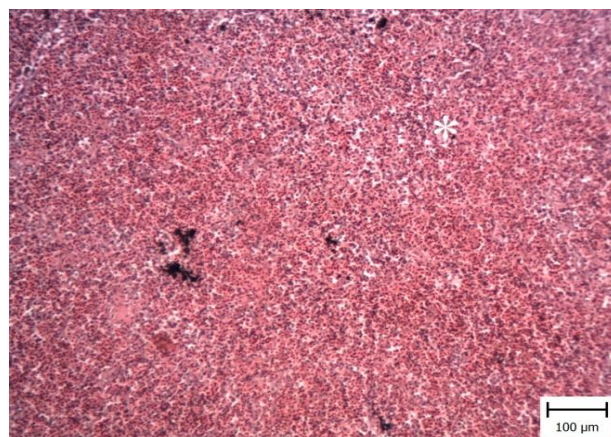


Figure 7: Spleen of Rainbow trout (*Onchorhynchus mykiss*). Increasing erythrocytes which are diffusely seen (white asterisk) (H&E, Bar: 100μm).

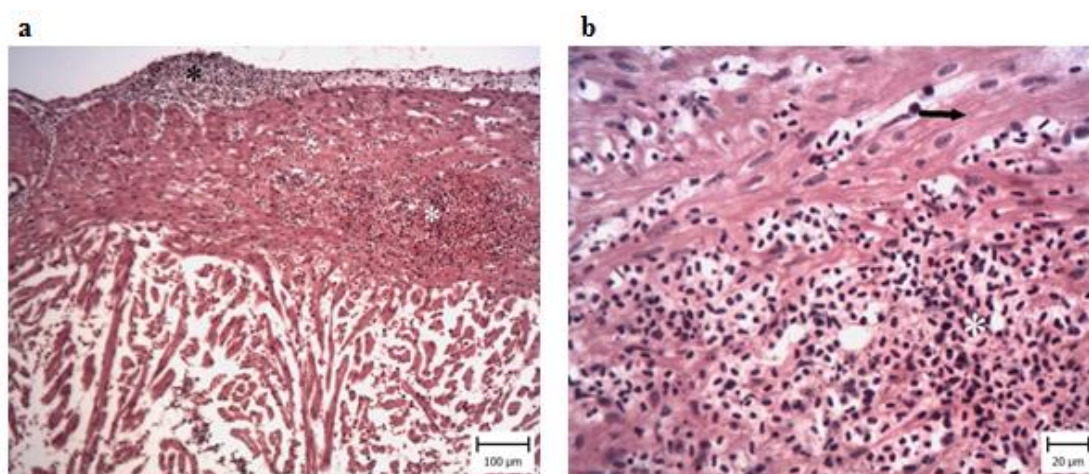


Figure 8: Heart of Rainbow trout (*Onchorhynchus mykiss*). a: Note haemorrhage between heart muscles (white asterisk) and beneath the epicardium (H&E, Bar: 100μm). b: A part of Figure 8a with higher magnification. Note accumulation of erythrocytes (white asterisk) between heart muscles (black arrow) (H&E, Bar: 100μm).

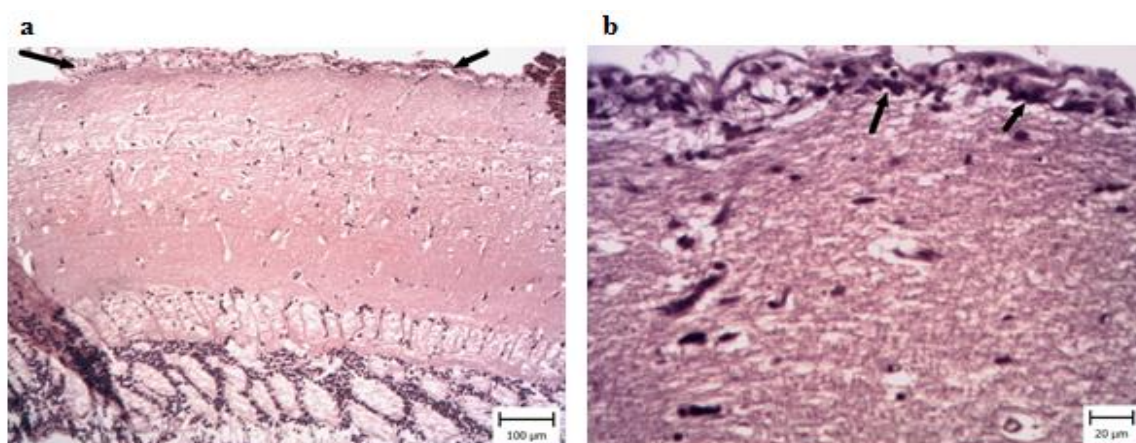


Figure 9 Mid-brain optic lobe of Rainbow trout (*Onchorhynchus mykiss*). a: Note prominent thickening of meninges (arrows) (H&E, Bar: 100μm). b: Optic lobe of Rainbow trout (*Onchorhynchus mykiss*). Note infiltration of mononuclear cells in the pia matter (arrows) (H&E, Bar: 20μm).

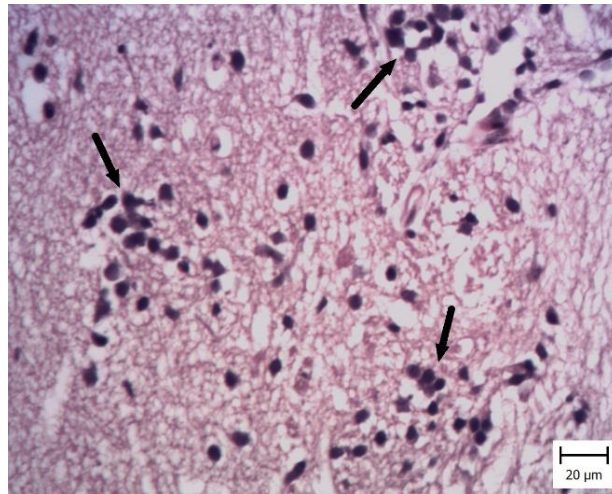


Figure 10: Mid brain of Rainbow trout (*Onchorhynchus mykiss*). Note gliosis which is characterized by accumulation of microglia (dark arrows) (H&E, Bar: 20μm).

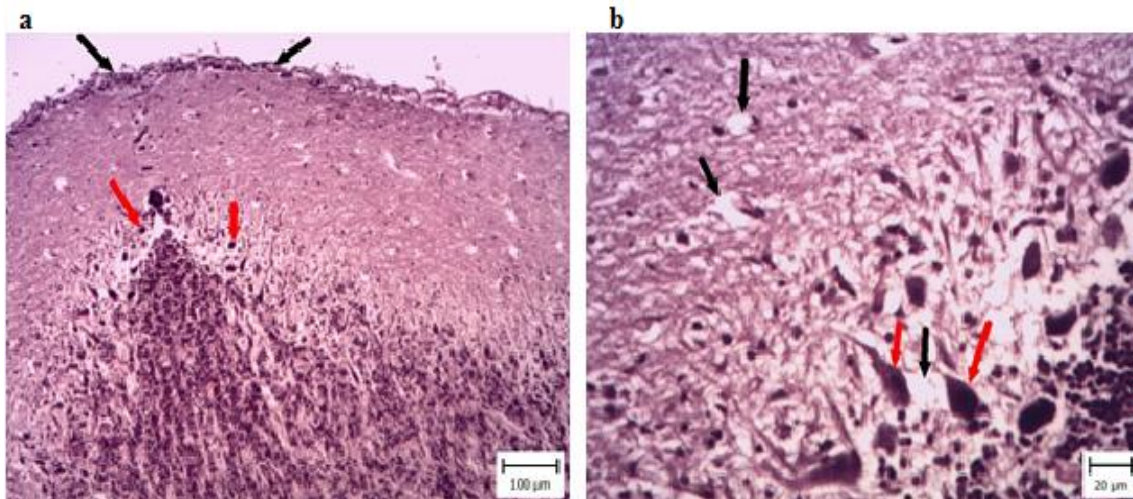


Figure 11: Cerebellum of Rainbow trout (*Onchorhynchus mykiss*). a: Thickening of pia matter (black arrows) and ischemic cell changes (red arrows) are obvious (H&E, Bar: 100μm). b: A part of picture 11a with higher magnification. Note ischemic cell changes of purkinje cells which have shrunk and dark (red arrows). Free spaces around them and vessels indicated increasing of Virchow robin space (dark arrows) (H&E, Bar: 20μm).

Discussion

Viral infections lead to economical and significant losses in the aquaculture industry and cause serious outbreaks. Therefore rapid identification of causative agents of fish diseases to control disease transmission is necessary. VHS is known as one of the most important fish disease which mainly affects

the rainbow trout (*O. mykiss*) farming industry and may represent an emerging risk for other fish species. Problems related to isolation and identification of viruses has led to the development of rapid and reliable tests including various RT-PCR, cell culture, immunohistochemistry and histopathology methods. For these

purposes sensitive and specific techniques for detection of VHSV, such as PCR and cell culture are necessary and also some other simple techniques like histopathology are useful to ensure the causative agent of disease.

Macroscopic pathology, molecular biology, histopathology, and virus isolation findings in this study fully confirm VHSV outbreak in the rainbow trout farms of Chaharmahal-Bakhtiari province in Western Iran, for the first time. The outbreak occurred in the intensive rainbow trout farming areas with detrimental impacts on the industry. The mortality in the affected farms was variable and different signs of disease were seen that had been related to several forms of the disease and the location of the farms.

The clinical and pathological results of this study are consistent with previously described features of VHS reported in rainbow trout (Yasutake and Rasmussen 1967; Brudeseth *et al.*, 2002; Kim and Faisal 2010a; Kim and Faisal, 2010b; Kim and Faisal 2011; Al-Hussinee *et al.*, 2011). Yasutake and Rasmussen (1967) carried out the first histopathology of the VHS in rainbow trout in an experimental infection. Their results indicate the kidneys as the primary target organ, followed by spleen, liver, pancreas, and adrenal cortex. Viral damage in the hematopoietic tissue (anterior kidney) is more severe than in the posterior region (Skall *et al.*, 2005).

In agreement with the other investigators (Raja-Halli *et al.*, 2006; Dale *et al.*, 2009), in the present study microscopic examination of kidney samples revealed severe necrosis of hematopoietic tissue and tissue replacement by erythrocytes (hemorrhage). Also, increased melanomacrophages centers and scattered black pigments were prominent findings that have also been reported by Raja-Halli *et al.* (2006) and Dale *et al.* (2009). Diffuse tubular degeneration was characterized with tubular cell vacuolation. Membranous glomerulonephritis with accumulation of eosinophilic materials in the urinary spaces (proteinuria) and extension of the glomerular space were also compatible with the findings of Kim and Faisal (2010a) and Kim and Faisal (2011). Eosinophilic intracytoplasmic inclusion bodies detected in the tubular cells were typical of the virus (Wolf, 1988). Viremia on day 1-4 post-infection exposes the endothelial cells to virus and related injury (Brudeseth *et al.*, 2002; Smail and Snow, 2011) and our findings on the early cases of the disease were indicative of extensive endothelial damage.

Hepatic sinusoid engorgement with blood, and focal to extensive necrobiotic changes, cytoplasmic vacuolation, pyknosis and karyolysis were further signs of viral damage to the liver. Interestingly, despite this clear

effect on hepatic morphology, Evensen *et al.* (1994) and Brudeseth *et al.* (2002) have shown that liver endothelial cells are not directly affected by VHSV and, thus, may lack the appropriate receptor for viral attachment. Kim and Faisal (2010a) compared susceptibility of some Great Lake fish species to North American viral haemorrhagic septicaemia virus. Their results showed all salmonids displayed significantly less pathological changes compared to other species. Rainbow trout liver tissues demonstrated multifocal areas of necrosis and degeneration, with vacuolation of hepatocyte containing pyknotic nuclei which was similarity noted in brook trout. Our findings are contrary to these reports, and trout displayed severe hepatic injuries that could be associated with viral pathogenicity and tropism. Also, the above mentioned researchers reported that largemouth bass was the only species to show congestion of the kidney. Typical histological changes are focal to multifocal degeneration and necrosis of a variety of tissues, although the pattern varies between species and virus genotypes (Issiki *et al.*, 2001; Brudeseth *et al.*, 2005; Lumsden *et al.*, 2007), and there can also be a vasculitis (Wolf, 1988; Lumsden *et al.*, 2007). Furthermore, changes associated with environmental and management factors, can further

complicate histopathological features of the disease.

Using cell culture-assisted virus isolation, molecular detection and histopathology, our study identified and confirmed the existence VHS disease in the region for the first time. Further studies are necessary to evaluate the isolated VHS virus in the region and to study the pathogenesis of the virus in experimentally infected rainbow trout.

Acknowledgments

The authors are grateful to Veterinary Faculty of Shahid Chamran University of Ahvaz for funding this work. Also, we would like to thank the Iranian Veterinary Organization and Central Veterinary Laboratory in particular for their assistance in this project.

References

- Ahmadi, M., Akhlaghi, M., Oryan, A. and Hosseini, A., 2011. Infectious pancreatic necrosis in a recirculating rainbow trout (*Oncorhynchus mykiss*) culture system. *Turkish Journal of Veterinary and Animal Sciences*, 35(5), 303-309.
- Al-Hussine, L., Lord, S., Stevenson, R.W., Casey, R.N., Groocock, G.H., Britt, K.L. and Lumsden, J.S., 2011. Immunohistochemistry and pathology of multiple Great Lakes fish from mortality events associated with viral haemorrhagic septicaemia virus type IVb. *Diseases of Aquatic Organisms*, 93(2), 117-127.

- Altinok, İ. and Kurt, İ., 2003.** Molecular diagnosis of fish diseases: a review. *Turkish Journal of Fisheries and Aquatic Sciences*, 3(2).
- Amlacher, E., Ude, J., Rudolph, C. and Ernst, G., 1980.** Direct electron microscopical visualization of the presumptive virus of viral haemorrhagic septicaemia (VHS) in the rainbow trout *Salmo gairdneri* Richardson and additional histopathological and haematological observations. *Journal of Fish Diseases*, 3(1), 55-62.
- Benmansour, A., Basurco, B., Monnier, A.F., Vende, P., Winton, J.R. and de Kinkelin, P., 1997.** Sequence variation of the glycoprotein gene identifies three distinct lineages within field isolates of viral haemorrhagic septicaemia virus, a fish rhabdovirus. *Journal of General Virology*, 78(11), 2837-2846.
- Brudeseth, B.E., Castric, J. and Evensen, Ø., 2002.** Studies on pathogenesis following single and double infection with viral hemorrhagic septicemia virus and infectious hematopoietic necrosis virus in rainbow trout (*Oncorhynchus mykiss*). *Veterinary Pathology Online*, 39(2), 180-189.
- Brudeseth, B.E., Raynard, R.S., King, J.A. and Evensen, Ø., 2005.** Sequential pathology after experimental infection with marine viral hemorrhagic septicemia virus isolates of low and high virulence in turbot (*Scophthalmus maximus* L.). *Veterinary Pathology Online*, 42(1), 9-18.
- Byon, J.Y., Ohira, T., Hirono, I. and Aoki, T., 2005.** Use of a cDNA microarray to study immunity against viral hemorrhagic septicemia (VHS) in Japanese flounder (*Paralichthys olivaceus*) following DNA vaccination. *Fish and Shellfish Immunology*, 18(2), 135-147.
- Collet, B., 2014.** Innate immune responses of salmonid fish to viral infections. *Developmental and Comparative Immunology*, 43(2), 160-173.
- Dadar, M., Memari, H.R., Vakharia, V.N., Peyghan, R., Shapouri, M.S. A., Mohammadian, T. and Ghasemi, M., 2015.** Protective and immunogenic effects of *Escherichia coli*-expressed infectious pancreatic necrosis virus (IPNV) VP2-VP3 fusion protein in rainbow trout. *Fish and Shellfish Immunology*, 47(1), 390-396.
- Dale, O.B., Ørpetveit, I., Lyngstad, T.M., Kahns, S., Skall, H.F., Olesen, N.J. and Dannevig, B.H., 2009.** Outbreak of viral haemorrhagic septicaemia (VHS) in seawater-farmed rainbow trout in Norway caused by VHS virus Genotype III. *Diseases of Aquatic Organisms*, 85(2), 93-103.
- Duesund, H., Nylund, S., Watanabe, K., Ottem, K.F. and Nylund, A., 2010.** Characterization of a VHS virus genotype III isolated from rainbow trout (*Oncorhynchus mykiss*) at a marine site on the west coast of Norway. *Virology Journal*, 7(1), 1.
- Einer-Jensen, K., Ahrens, P., Forsberg, R. and Lorenzen, N., 2004.** Evolution of the fish

- rhabdovirus viral haemorrhagic septicaemia virus. *Journal of General Virology*, 85(5), 1167-1179.
- Elsayed, E., Faisal, M., Thomas, M., Whelan, G., Batts, W. and Winton, J., 2006.** Isolation of viral haemorrhagic septicaemia virus from muskellunge, *Esox masquinongy* (Mitchill), in Lake St Clair, Michigan, USA reveals a new sublineage of the North American genotype. *Journal of Fish Diseases*, 29(10), 611-619.
- Estepa, A., Frías, D. and Coll, J.M., 1993.** In vitro susceptibility of rainbow trout fin cells to viral haemorrhagic septicaemia virus. *Diseases of Aquatic Organisms*, 15, 35-35.
- Evensen, Ø., Meier, W., Wahli, T., Olesen, N.J., Vestergård Jørgensen, P.E. and Håstein, T., 1994.** Comparison of immunohistochemistry and virus cultivation for detection of viral haemorrhagic septicaemia virus in experimentally infected rainbow trout *Oncorhynchus mykiss*. *Diseases of Aquatic Organisms*, 20(2), 101-109.
- Fisheries FA. Aquaculture Department. 2013.** Global aquaculture production statistics for the year. 2010. 52 P.
- Garver, K.A., Traxler, G.S., Hawley, L.M., Richard, J., Ross, J.P. and Lovy, J., 2013.** Molecular epidemiology of viral haemorrhagic septicaemia virus (VHSV) in British Columbia, Canada, reveals transmission from wild to farmed fish. *Diseases of Aquatic Organisms*, 104(2), 93-104.
- Isshiki, T., Nishizawa, T., Kobayashi, T., Nagano, T. and Miyazaki, T., 2001.** An outbreak of VHSV (viral haemorrhagic septicaemia virus) infection in farmed Japanese flounder *Paralichthys olivaceus* in Japan. *Diseases of Aquatic Organisms*, 47(2), 87-99.
- Kim, R. and Faisal, M., 2010a.** Comparative susceptibility of representative Great Lakes fish species to the North American viral hemorrhagic septicemia virus Sublineage IVb. *Diseases of Aquatic Organisms*, 91(1), 23-34.
- Kim, R. and Faisal, M., 2010b.** Comparative susceptibility of representative Great Lakes fish species to the North American viral haemorrhagic septicaemia virus Sublineage IVb. *Diseases of Aquatic Organisms*, 91(1), 23-34.
- Kim, R. and Faisal, M., 2011.** Emergence and resurgence of the viral haemorrhagic septicaemia virus (*Novirhabdovirus*, *Rhabdoviridae*, *Mononegavirales*). *Journal of Advanced Research*, 2(1), 9-23.
- Lorenzen, E., Carstenen, B. and Olesen, N.J., 1999.** Inter-laboratory comparison of cell lines for susceptibility to three viruses: VHSV, IHNV and IPNV. *Diseases of Aquatic Organisms*, 37(2), 81-88.
- Lumsden, J.S., Morrison, B., Yason, C., Russell, S., Young, K., Yazdanpanah, A. and Way, K., 2007.** Mortality event in freshwater drum *Aplodinotus grunniens* from Lake Ontario, Canada, associated

- with viral haemorrhagic septicemia virus, Type IV. *Diseases of Aquatic Organisms*, 76(2), 99.
- Moran, D. and Fofana, A., 2007.** An economic evaluation of the control of three notifiable fish diseases in the United Kingdom. *Preventive Veterinary Medicine*, 80(2), 193-208.
- Nishizawa, T., Iida, H., Takano, R., Isshiki, T., Nakajima, K. and Muroga, K., 2002.** Genetic relatedness among Japanese, American and European isolates of viral hemorrhagic septicemia virus (VHSV) based on partial G and P genes. *Diseases of Aquatic Organisms*, 48(2), 143-148.
- OIE. Manual of diagnostic tests for aquatic animals. 2009.** Chapter 2.3.9; viral haemorrhagic septicaemia. World Organization for Animal Health. pp. 279-298.
- Pierce, L.R., Willey, J.C., Palsule, V.V., Yeo, J., Shepherd, B.S., Crawford, E.L. and Stepien, C.A., 2013.** Accurate detection and quantification of the fish viral hemorrhagic septicemia virus (VHSV) with a two-color fluorometric real-time PCR assay. *PloS one*, 8(8), e71851.
- Rahnema, R., Seyfi Abad Shapouri, M.R., Peyghan, R., Rezaie, A. and Shahbazian, N., 2018.** Cloning and expression of the constant region of rainbow trout (*Onchorhynchus mykiss*) μ immunoglobulin chain in *Escherichia coli*. *Iranian Journal of Fisheries Sciences*, 17(3), 573-584.
- Raja-Halli, M., Vehmas, T.K., Rimaila-Pärnänen, E., Sainmaa, S., Skall, H.F., Olesen, N.J. and Tapiovaara, H., 2006.** Viral haemorrhagic septicaemia (VHS) outbreaks in Finnish rainbow trout farms. *Diseases of Aquatic Organisms*, 72(3), 201-211.
- Skall, H.F., Slierendrecht, W.J., King, J.A. and Olesen, N.J., 2004.** Experimental infection of rainbow trout *Oncorhynchus mykiss* with viral haemorrhagic septicaemia virus isolates from European marine and farmed fishes. *Diseases of Aquatic Organisms*, 58(2-3), 99-110.
- Skall, H.F., Olesen, N.J. and Møllergaard, S., 2005.** Viral haemorrhagic septicaemia virus in marine fish and its implications for fish farming—a review. *Journal of Fish Diseases*, 28(9), 509-529.
- Smail, D.A. and Snow, M., 2011.** 3 Viral haemorrhagic septicaemia. *Fish Diseases and Disorders*, 3, 110.
- Snow, M., King, J.A., Garden, A., Shanks, A.M. and Raynard, R.S., 2005.** Comparative susceptibility of turbot *Scophthalmus maximus* to different genotypes of viral haemorrhagic septicaemia virus. *Diseases of Aquatic Organisms*, 67(1-2), 31-38.
- Soliman, H. and El-Matbouli, M., 2006.** Reverse transcription loop-mediated isothermal amplification (RT-LAMP) for rapid detection of viral hemorrhagic septicaemia virus (VHS). *Veterinary Microbiology*, 114(3), 205-213.
- Thiery, R., De Boisseson, C., Jeffroy, J., Castric, J., De Kinkelin, P. and Benmansour, A., 2002.** Phylogenetic analysis of viral

haemorrhagic septicaemia virus (VHSV) isolates from France (1971-1999). *Diseases of Aquatic Organisms*, 52(1), 29-37.

Vinay, T.N., Kim, Y.J., Jung, M.H., Kim, W.S., Kim, D.H. and Jung, S.J., 2013. Inactivated vaccine against viral hemorrhagic septicemia (VHS) emulsified with squalene and aluminum hydroxide adjuvant provides long term protection in olive flounder (*Paralichthys olivaceus*). *Vaccine*, 31(41), 4603-4610.

Wolf, K., 1988. Fish viruses and fish viral disease. Cornell University Press, Ithaca, NY. 476 P.

Yasutake, W.T. and Snieszko, S., 1970. Comparative histopathology of epizootic salmonid virus diseases. In Symposium on diseases of fishes. pp. 341-350.

Yasutake, W.T. and Rasmussen, C.J., 1967. Histopathogenesis of experimentally induced viral hemorrhagic septicemia in fingerling rainbow trout (*Salmo gairdneri*). *Bulletin-Office International des Epizooties*, 69(7), 977-984.